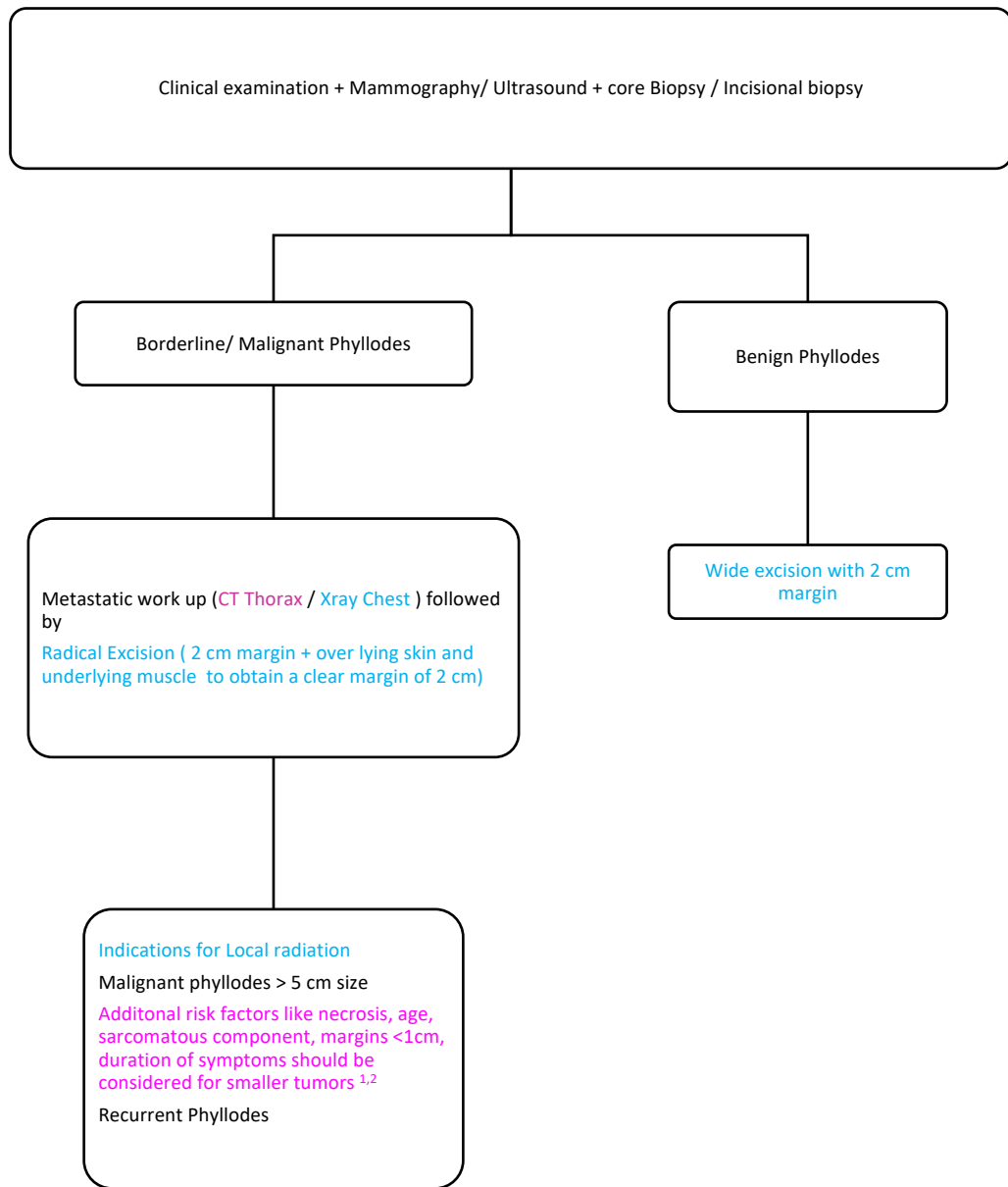


## Management of Phyllodes tumour of the breast



- Radical mastectomy or lumpectomy can be considered depending on T size and Breast vs Tumour ration. Conservation can be offered if cosmetically acceptable outcome possible without compromising on margins
- Follow up: Clinical Breast exam: Every 6 months, Breast imaging every 18 to 24 months, Lung imaging in case of malignant histology with sarcomatous component every 12 months.<sup>3</sup>

**References:**

1. Parham Khosravi-Shahi. Management of non-metastatic phyllodes tumors of the breast: Review of the literature. *Surgical Oncology* 20 (2011) e143-e148
2. Wadasadawala T, Swain M, Bajpai J. Phyllodes tumor of the breast: Wolf inside the sheep's skin! *Oncobiology and Targets* 3(2016):10.
3. Gamboa AC, Ethun CG et al. Lung Surveillance Strategy for High-Grade Soft Tissue Sarcomas: Chest X-Ray or CT Scan?. *J Am Coll Surg*. 2019 Aug 1. pii: S1072-7515(19)30446-6. doi: 10.1016/j.jamcollsurg.2019.07.010. [Epub ahead of print]